J Neurosurg Spine 17:292–299, 2012

Primary chordomas of the cervical spine: a consecutive series of 14 surgically managed cases

Clinical article

Yu Wang, M.D.,[1] Jianru Xiao, M.D.,[1] Zhipeng Wu, M.D.,[1] Quan Huang, M.D.,[1] Wending Huang, M.D.,[1] Qing Zhu, M.D.,[1] Zaijun Lin, M.D.,[1] and Liangzhe Wang, M.D.[2]

[1]The Spinal Tumor Center and [2]Department of Pathology, Changzheng Hospital, Second Military Medical University, Shanghai, China

Object. Cervical chordomas are rare lesions and usually bring about challenges in treatment planning because of their wide extension and complicated adjacent anatomy. There are few large published series at present focusing on cervical chordomas. The authors studied a consecutive series of 14 patients with primary cervical chordomas who underwent surgical treatment and were observed between 1989 and 2008. By reviewing the clinical patterns and follow-up data, they sought to investigate the clinical characters, tailor the appropriate surgical techniques, and establish prognosis factors for cervical chordomas.

Methods. Hospitalization and follow-up data in the 14 patients were collected. All patients underwent piecemeal tumor excision and reconstruction for stability; total spondylectomy was achieved in 5 cases. Postoperative radiotherapy was administered in all patients. Kaplan-Meier plots were used to represent tumor recurrence and patient survival, and log-rank testing was used to determine the risk factors of local recurrence.

Results. Follow-up ranged from 8 to 120 months (mean 58.6 months). Symptom and neural status in most patients improved after surgery. The 1- and 5-year disease-free survival rates were 78.6% and 50%, respectively, and the 1- and 5-year survival rates were 92.9% and 85.7%, respectively. Log-rank tests revealed that the following variables were significantly associated with a high rate of tumor recurrence: age less than 40 years or greater than 70 years ($p = 0.006$) and an upper cervical tumor location ($p = 0.019$).

Conclusions. Chordomas in the cervical spine are usually neoplasms that exhibit insidious growth and a wide extension by the time of diagnosis. Radical intralesional debulking surgery and postoperative radiotherapy have been effective treatment. A limited application of en bloc tumor resection and the highly likely intraoperative intralesional tumor seeding may partially explain the high local recurrence rate, whereas the chance of distant metastases, fortunately, is very low. Most recurrence were documented within 3 years. Some specific surgical techniques should be emphasized to minimize tumor seeding. Patients with upper cervical chordomas, younger adults, and elderly adults have worse prognosis. For patients with chordoma extending to both the anterior and posterior spinal columns, total spondylectomy combined with piecemeal excision is recommended for a better prognosis.
(http://thejns.org/doi/abs/10.3171/2012.7.SPINE12175)

Key Words • **chordoma** • **cervical spine** • **case series** • **outcome**

Chordomas are rare and aggressive primary malignancies derived from notochord renmants.[11] Despite the lesion's slow expansion rate, the tumor is often quite large when first discovered, which results in difficulties in the surgical treatment and sometimes leads to a high local recurrence rate and a poor survival rate.[2,27] Cervical chordomas growing in a highly risky anatomical region, although rare (approximately 5% of all chordomas), pose a challenge to surgeons performing en bloc resection or even complete excision.[7,35,36] Single case reports represents most of the literature on cervical chordomas, but a small portion of the literature comprises small series or cases included in general reviews of spinal lesions. It follows, then, that paucity of available clinical evidence hinders clinicians in treatment planning and prognosis predictions.

This article contains some figures that are displayed in color online but in black-and-white in the print edition.

Abbreviation used in this paper: WBB = Weinstein-Boriani-Biagini.

In the present study, we retrospectively reviewed 14 consecutive patients with primary cervical chordomas surgically treated in our institute from 1989 to 2008. Clinical data obtained from medical records and follow-up results are presented in an attempt to explore the clinical characters, surgical technique, and prognosis-predicting factors for cervical chordomas.

Methods

Epidemiology

A total of 14 patients (8 males and 6 females, mean age 54.2 years [range 17–74 years]) were included in this series. In 5 patients lesions involved the upper cervical spine (C1–2), and in 9 patients lesions involved the lower cervical spine. The tumor was limited to 1 vertebral level in 10 patients and multiple levels in 4 (2 levels in 3 patients and 5 levels in 1 patient). All patients had primary tumors, and none had a history of surgical treatment.

Preoperative atypical symptoms were present for 1–12 months (mean 6.1 months). Progressive pain in the neck, shoulders, or upper limbs was the most common complaint (in 92.9% or 13 of 14 patients), among which radicular pain occurred in 8 patients (57.1%). Seven patients (50%) experienced aggravated pain at nighttime. Additionally, symptoms of cord compression, at different degrees, were observed in 10 patients (71.4%), 2 of whom had paraplegia. Two patients (Cases 1 and 10) presented with dysphagia, and 1 patient (Case 11) presented with neck stiffness (Table 1).

The neurological status of all the patients was evaluated and classified according to the following 5-point scheme: Grade 1, normal ambulation; Grade 2, bilateral lower-extremity weakness with the ability to ambulate not requiring assistance; Grade 3, bilateral lower-extremity weakness with the ability to ambulate requiring assistance; Grade 4, inability to ambulate with movable lower extremities; and Grade 5, paraplegia (Table 1).[37]

Imaging and Staging

Plain radiographs, CT scans, and MR images were acquired in all cases. Radiographically documented bone destruction or erosion was observed in 8 patients. Computed tomography detected collapsed vertebrae in 5 patients and subluxation of the local cervical spine in 3 patients. Magnetic resonance imaging is the best modality for detecting tumors at present. On T1-weighted images tumors were isointense (8 cases) or hypointense (6 cases), while on T2-weighted images, all lesions were hyperintense. All patients had perivertebral soft-tissue involvement of the tumor, and the vertebral artery was involved in 10 cases (71.4%), among which 3 of the arteries were encased.

The extension of the tumors was determined using the WBB classification,[9] which bases its classification of layers and zones on CT and MRI findings. As a result, the tumors in most cases involved Layers A–D, with only 1 lesion extended to Layers A–C. The lesions were found to involve only the anterior column (Zones 4–9) in 6 cases (42.9%), whereas they extending to both the anterior and the posterior columns in 8 cases (57.1%).

Treatment

Surgical planning was based on tumor extension according to the WBB system and a patient's general health status. In the 8 patients with both the anterior and the posterior elements involved, a combined anterior-posterior approach was used for tumor resection and spinal reconstruction in 7 patients, and an anterior approach was used in the remaining patient because of his poor health status. The anterior approach was used for tumor resection in the 6 patients with anterior column involvement, with 3 of these 6 patients also requiring a posterior approach for reconstruction. Of 5 patients with upper cervical chordomas, the transoral approach was employed in 1 and the extraoral approach (retropharyngeal approach) in 4. All the surgeries were completed in 1 stage. Total spondylectomy combined with piecemeal excision was performed in 5 cases (Figs. 1 and 2 show total spondylectomy in 2 cases). Complete tumor removal was achieved in 12 cases, whereas tumor remnants were detected on postoperative MRI in 2 patients (Cases 1 and 9).

Patients with lower cervical spine chordomas underwent anterior reconstruction (titanium mesh cage and titanium locking plate) and posterior reconstruction (pedicle screw system). Of the 5 patients with upper cervical chordomas, an anterior titanium mesh cage combined with a titanium locking plate was applied only in 1 patient (Case 9 [as only the anterior approach was adopted for this patient]), whereas occipitocervical fusion (bone graft combined with occipitocervical internal fixation) was undertaken in 3 patients and pure occipitocervical internal fixation in 1 patient. During the reconstruction for vertebral stability, anterior titanium mesh filled with bone cement was used to replace the vertebral body in 6 patients, and titanium mesh filled with autogenous bone was used in 4 patients.

All patients underwent adjuvant radiation therapy postoperatively. The total radiation dose ranged from 44 to 80 Gy (mean 63.7 Gy) (Table 1). Chemotherapy was not administered in any case.

Pathology

Histological diagnoses were established in all cases during or after surgery; in all cases conventional chordomas were demonstrated. Neither chondroid chordomas nor dedifferentiated lesions were seen.

Clinical Follow-Up

Postoperative radiography, CT, and MRI studies were acquired in all cases to monitor spinal instability or fusion and the existence of tumor remnant, local recurrence, or metastasis. Conventional studies were obtained 3, 6, and 12 months after surgery during the 1st year, every 6 months for the following 2 years, and annually thereafter for the rest of each patient's life. Follow-up data were obtained through office visits and telephone interviews. Neurological status and other clinical symptoms were evaluated 2–3 months after surgeries. Results were established after the last operation for patients who underwent multiple surgeries in this study.

TABLE 1: Clinical data obtained in 14 patients with cervical chordomas*

					Preop Status		Treatment				Follow-Up (mos)			
Case No.	Age (yrs), Sex	Location	VAI	WBB Stage†	SxD (mos)	5-Point Scale‡	Approach	Resection Mode	Complication	RT Dose (Gy)	5-Point Scale‡	Period	Local Recurrence§	Final
1	34, F	C1–2	yes	4-7/A-D	6	1	TO, PT	subtotal	none	60	2	120	yes, 12	AWD
2	50, F	C-2	no	5-8/A-D	3	5	AT-PT	subtotal	none	60	2	72	yes, 36	AWD
3	54, M	C-5	yes	3-11/A-D	3	4	AT-PT	total	none	44	1	36	no	NED
4	38, M	C-5	no	5-8/A-D	6	4	AT	subtotal	none	70	1	48	no	NED
5	72, M	C4–5	yes	7-11/A-D	6	5	AT-PT	subtotal	none	44	3	60	yes, 30	AWD
6	64, M	C-3	yes	3-10/A-D	6	4	AT-PT	total	none	70	2	66	yes, 37	AWD
7	17, F	C2–3	yes	1-8/A-D	6	1	AT-PT	subtotal	none	70	1	8	yes, 6	DOD
8	61, F	C-4	yes	1-11/A-D	3	2	AT-PT	total	none	80	1	72	no	NED
9	74, M	C-2	yes	3-10/A-D	3	4	AT	subtotal	pulmonary infection, delirium	60	3	18	yes, 10	DOD
10	51, M	C4–T1	no	5-8/A-C	1	1	AT	subtotal	none	66	1	92	no	NED
11	74, M	C-3	yes	11-8/A-D	6	3	AT-PT	total	lt shoulder weakness	66	1	60	yes, 24	AWD
12	63, M	C-5	yes	2-8/A-D	12	3	AT-PT	total	none	70	1	48	no	NED
13	65, F	C-2	no	5-8/A-D	12	4	AT-PT	subtotal	none	66	1	36	no	NED
14	42, F	C-3	yes	5-9/A-D	12	1	AT	subtotal	none	66	1	84	yes, 84	AWD

* AT = anterior; AWD = alive with disease; DOD = died of disease; NED = no evidence of disease; PT = posterior; RT = radiotherapy; SxD = symptom duration; TO = transoral; VAI = vertebral artery involvement.

† Numerals indicate zones and letters indicate the layers in the WBB classification scheme.

‡ See *Epidemiology* section for the definition of scale scores.

§ Values indicate months between first surgery and first recurrence.

Fig. 1. Case 8. Studies obtained in a 61-year-old-woman with a huge primary chordoma of C-4. Sagittal MR image **(A)** and axial CT scan **(B)** showing a huge mass on the C-4 vertebra, bilateral pedicles, and left lamina, with the lesion extending into the spinal canal and encasing the vertebral artery bilaterally. A combined anterior-posterior approach with a total spondylectomy was performed in 1 stage. A titanium plate and a titanium mesh cage filled with bone cement were used for anterior reconstruction, and pedicle screws and rods were applied in the posterior approach **(C and D)**. The patient was followed up for 6 years and no tumor recurrence was observed.

Fig. 2. Case 6. Studies obtained in a 64-year-old man with a huge primary chordoma of C-3. Sagittal **(A)** and axial **(B)** MR images showing that the neoplasm invaded both the vertebral body and posterior elements and formed a large perivertebral mass. A combined anterior-posterior approach with a total spondylectomy was performed in 1 stage. A titanium plate and a titanium mesh cage filled with bone cement were used for anterior reconstruction, and pedicle screws and rods were applied for the reconstruction of the spine **(C and D)**.

Statistical Analysis

Survivorship analysis was conducted. Kaplan-Meier plots were used to determine the tumor recurrence and patient survival. In establishing risk factors for tumor recurrence, the independent variables were as follows: age when first diagnosed; sex; tumor location (upper cervical or lower cervical spine); tumor extension (single or multiple vertebrae, only anterior column, or 2 columns involved, anatomical relationship with the vertebral artery); the 5-point scale before surgery; the surgical mode, and radiotherapy dose. The dependent variable was the patient's postoperative continuous disease-free survival time. The log-rank test was used to perform statistical analysis. All statistical analyses were performed using SPSS (version 16.0, IBM). Statistical significance was set at $p < 0.05$.

Results

Intraoperative blood loss ranged from 300 to 1600 ml (mean 1042.9 ml), and the operative durations ranged from 2.5 to 5.7 hours (mean 4.25 hours). The bone graft fusion rate was 100%, and no instances of spinal instability were observed. No patient died during the surgeries. During the follow-up visit 2–3 months after the last surgery, the 10 patients who presented with cord compression had neurological scores (using the 5-point scheme) that had diminished by 1–3 grades (Table 1). Other symptoms, such as neck pain, radicular pain, and dysphagia in all patients, were also relieved to different degrees after the last operation.

Complications

No intraoperative complications occurred. Postoperatively, 1 patient (Case 9) suffered a lung infection and delirium and recovered after treatment, while another patient (Case 11) complained of left shoulder weakness, which may have been precipitated by the traction of the nerve root during the operation, but the weakness resolved within 2 months. In both cases of postoperative complications, the patients were over 70 years of age.

Local Control and Survival

All the patients underwent follow-up for a duration

ranging from 8 to 120 months (mean 58.6 months). Local tumor recurrence was documented in 8 (57.1%) of 14 patients, and no metastasis was demonstrated. Tumor recurrences were noted during follow-up examination 6–84 months (mean 29.9 months) after the first surgery at our institute; the 1- and 5-year disease-free survival rates were 78.6% and 50%, respectively (Fig. 3 upper). Among patients with tumor recurrence, one (Case 6) underwent further surgery but, unfortunately, tumor recurrence was again observed after the operation. Another patient (Case 9) underwent 2 further surgeries but died shortly after the second operation. Three patients (Cases 1, 2, and 5) received further adjusted radiation therapy, and the tumors were reduced in size in Cases 1 and 2, whereas the lesion remain unchanged in Case 5.

At the end of the follow-up, 2 patients had unfortunately died: one patient (Case 9) died of the postoperative pulmonary infection, and the other (Case 7) died of local recurrence and tumor extension. The survival durations of these 2 patients after the first surgery in our institute were 8 (Case 7) and 18 (Case 9) months, and 1- and 5-year survival rates were 92.9% and 85.7%, respectively (Fig. 3 lower).

The results of the log-rank test indicated that there were 2 significant contributors to tumor local recurrence: 1) the younger age (< 40 years) or the older age (> 70 years) (p = 0.006); and 2) upper cervical location (p = 0.019) (Fig. 4). Not significantly associated with tumor recurrence were the following: sex, tumor extension, the 5-point scale before surgery, and surgical mode and radiotherapy dose.

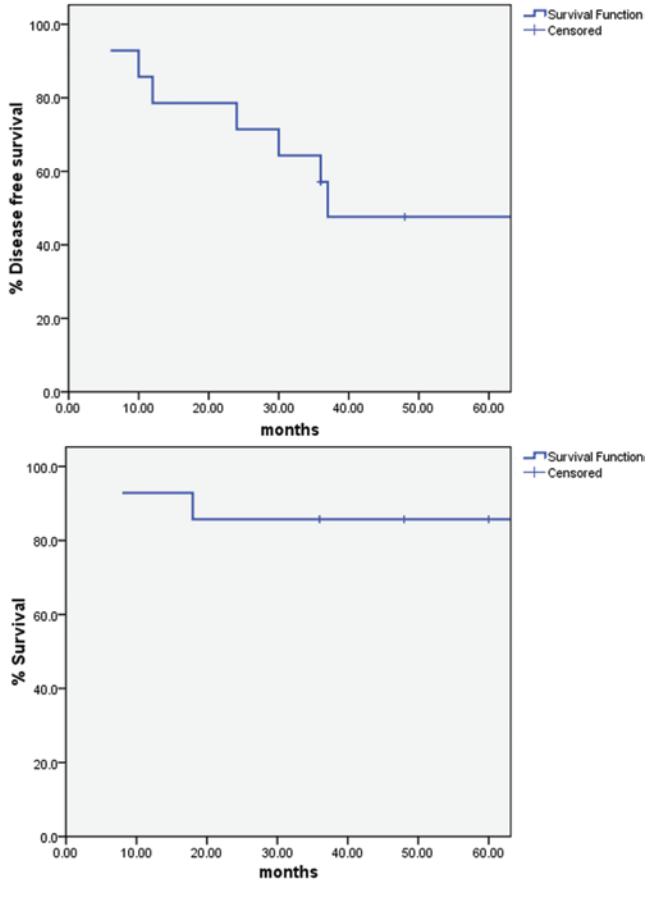

Fig. 3. Graphs of Kaplan-Meier analyses showing the disease-free survival rate **(upper)** and the survival rate **(lower)** in a series of 14 patients.

Discussion

Studies on rare cervical chordomas[23,28] are helpful in revealing clinical characters of the tumor, which further provide evidence for diagnosis and treatment of this disease. In 14 patients included in the present study, the mean age (± SD) of the patients was 54.2 ± 16.8 years. It is traditionally believed that the age of patients with chordoma typically ranges from 50 to 70 years,[15,17,32] but the age of 50% of our patients is not consistent with this range. This discrepancy may imply that the age range is not as strict as previously thought. In our series, the size of the tumors was usually massive when diagnosed: tumors spanning multiple vertebral levels were seen in 4 cases, and tumors extending into both the anterior and posterior column (according to WBBwerestage) were found in 8 cases; all the lesions invaded the perivertebral soft tissue, and the vertebral artery was affected in 10 cases. However, the mean prediagnosis duration of symptoms was relatively short—just 6.6 months. Moreover, chordomas are thought to be slow-growing tumors. Thus, chordomas, especially those

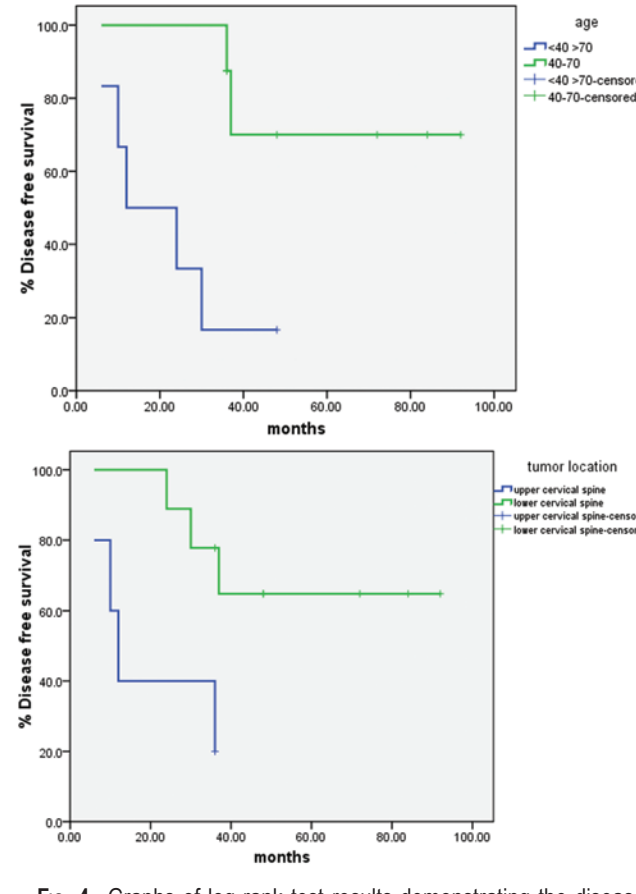

Fig. 4. Graphs of log-rank test results demonstrating the disease-free survival curve based on age **(upper)** and tumor location **(lower)**.

affecting the cervical spine, represent insidious tumors. The reported metastatic rate of chordomas ranges from 10% to 48%.[11,14,18] These metastases are usually accompanied by sacrococcygeal chordomas. We found no distant or neuraxis metastases in this series, even in patients with longer-term follow-up. This may be another specific feature of cervical chordomas.

The Kaplan-Meier estimates indicated a 5-year disease-free survival rate and a 5-year survival rate of 50% and 85.7%, respectively, and they demonstrated that most recurrence events appeared within 3 years of initial surgeries. This information may support the need for more frequent follow-up in the initial 3 years postoperatively. However, 1 patient (Case 14) suffered a local tumor recurrence in the 7th year after the initial surgery. Late tumor recurrences have also been reported by other authors,[8,23] indicating that long-term follow-up evaluations are necessary for patients with cervical chordomas. No patients in our series underwent en bloc tumor resection predominantly for the wide extension of their tumor. Cloyd et al.[12] analyzed 12 cases of cervical chordoma managed with en bloc surgery and reported that the 5-year disease-free survival rate reached 75% despite a short follow-up period not exceeding 24 months in 6 of 12 patients. Similarly, Molina et al.[29] reported a series of cervical chordomas managed with en bloc surgery; the 5-year disease-free survival rate was 58.3% in an average follow-up period of 42 months. Although it has been proven that en bloc resection is the most effective procedure for improving survival states of chordoma patients,[6,8,10,33] this may not be the case for patients with cervical chordomas because of the risky anatomy in the cervical spine region. Barrenechea et al.[4] argued that en bloc resection of cervical chordomas was not feasible and that intralesional radical resection remained effective. Leitner et al.[24] suggested that only small tumors in the vertebral body not expanding into Layer D were suitable for en bloc resection. In most en bloc resection case reports,[12,29] the predominant bias lies in the relatively short follow-up period. Theoretically speaking, en bloc resection can maximize the removal of the tumor mass to avoid recurrence. However, in most cases of widely invading cervical chordomas, a wide tumor margin is hard to achieve (wide tumor margin was possible in only 2 of 12 cases in the study reported by Molina et al.), and the local vertebral arteries and nerve roots have to be sacrificed for tumor resection, which may lead to a poor postoperative quality of life. In the elderly or patients in poor health, severe surgical injuries could be a disaster. For instance, the mean blood loss and the operative duration in our series were 1042.9 ml and 4.25 hours, respectively, while they were 2900 ml and 11 hours, respectively, in en bloc cases in patients reported by Cloyd et al.[12] Therefore, considering the risk-benefit ratio, en bloc tumor resection should only be undertaken in patients with cervical chordoma that are limited within the vertebral body. In our series, the 5-year disease-free survival rate in patients with primary cervical chordomas was 50% (in contrast, it was 58.3% in the en bloc resection group reported by Molina et al.), which may prove that radical piecemeal tumor resection combined with postoperative radiotherapy is an effective approach for cervical chordomas. The log-rank test demonstrated that upper-level cervical chordomas are related to a worse prognosis, which is a finding supported by various reports in the literature.[29,39] It is well known that clear exposure in the upper cervical region is more challenging than in the lower cervical region,[26,38] and therefore complete resection of the tumor tissue can be very difficult sometimes due to the complicated nearby structures. In our series, incomplete tumor removal was detected in 2 patients (Cases 1 and 9) in whom tumors were present in the upper cervical vertebrae.

A younger age (< 40 years) or an older age (> 70 years) in chordoma patients was also associated with a worse outcome. It is generally believed that the chordomas in childhood and adolescence are more variable histologically and exhibit a more aggressive clinical course than those in adults.[13,21,25,34] However, recent large series studies have indicated that the overall survival rate in pediatric patients with chordomas was no worse than the rate in adults and that a dedifferentiated subtype of chordoma is significantly associated with a worse prognosis.[19,31] For chordomas in older patients, Jawad and Scully,[22] in an analysis of 962 patients, demonstrated that age greater than 59 years is an independent predictor of poor outcome. In our series, all chordomas were shown to be histologically conventional. Therefore, the location of the tumor, instead of tumor subtype, may play a role in contributing to a worse prognosis in younger elderly adults: upper cervical chordomas were present in 3 of 6 patients in the group of patients who were less than 40 years or greater than 70 years, whereas upper cervical chordomas were present in 2 of 8 patients in the 40- to 70-year-old group. Despite the aforementioned results, a more exact histological subtyping system may be needed for further prediction of prognoses.

Although total spondylectomy has been believed to be able to permit excision of all likely contaminated bone structures, ensuring a radical removal of the neoplasms,[1] this procedure was not significantly related to better local recurrence control in the log-rank test. In our series, we failed to find any tumor limited to a single anterior column excised by total spondylectomy. By comparing patients with tumors extending to both columns in the total and subtotal spondylectomy groups, the prognosis in the total-spondylectomy group was found to be much better than that of the other group (Table 2). This finding implies that total spondylectomy is beneficial for tumors in a dual-column location but may be unnecessary for tumors limited to a single column, and surgical planning should be decided by using the WBB stage.

Based on our observations during surgery, cervical chordomas, similar to chordomas located in other regions, are tumors with less vasculature, despite the fact that we often encounter heavy bleeding intraoperatively, which is probably due to the aggressive extension of the neoplasm encasing the surrounding abundant vasculatures. Therefore, adequate hemostasis before removing the tumor mass is also a key step in total tumor resection. Cervical chordomas are relatively fluid compared with other solid tumors and can easily break through the bony cortex; additionally they are prone to invade the paraver-

TABLE 2: Outcome in patients with anterior- and posterior-column tumors stratified by having undergone total spondylectomy or subtotal spondylectomy

Spondylectomy Group	No. of Cases	No. of Patients (mos)			
		Local Recurrence	NED	AWD	DOD
total	5	2 (24, 37)*	3 (52 [36–72])†	2 (66, 60)*	0
subtotal	3	3 (15.3 [6–30])†	0	1 (60)*	2 (8, 18)*

* Values represent the number of months since the first surgery in each patient.
† Values represent the mean number and range of months since the first surgery in each patient.

tebral soft tissue. Paravertebral lesions can sometimes be much larger than the original vertebral lesion, as exemplified in one of our cases. The paravertebral tumor in Case 10 expanded from C-4 to T-1. As the tumor spreads along the paravertebral muscles, it should be more amenable to total excision of the contaminated muscles even if the muscles are not fully invaded by the lesion, as documented on MRI. The fluidity feature of cervical chordomas makes them capable of seeding in the surgical field, which may also partly explain the following: 1) the high rate of tumor recurrence; and 2) the larger-size paravertebral lesion observed in recurrent cases. To minimize tumor seeding, we usually irrigate the surgical field copiously with cisplatin-containing deionized water and try to complete the combined anterior-posterior procedure in a single stage.

Unilateral vertebral artery ligation is thought to be safe if the bilateral vertebral arteries have been sufficiently assessed preoperatively.[3,20] In our series, unilateral vertebral artery ligation was performed in 3 earlier cases and no related complications were observed. Nevertheless, we began to doubt the value of ligation in our piecemeal tumor excisions; we found that carefully dividing the vertebral arteries from the tumor mass with an operating megaloscope under proper exposure was also effective in avoiding probable ischemia. Opening the transverse foramen and exposing the vertebral artery before resecting the chordoma is the key to preserving the vertebral artery.

Considering the malignant nature and high local recurrence rate of cervical chordomas, we prefer bone cement to autogenous bone for filling anterior titanium mesh cages; the substance not only provides immediate local stability but also kills potentially remaining tumor cells through heat release, thus setting barriers to tumor recurrence.

Several articles have reported that high-dose radiotherapy for cervical chordomas is effective and safe.[5,16,30] All patients in the present study underwent radiotherapy after intralesional excision. Nevertheless, the log-rank test did not correlate to the high-dose radiotherapy with better local recurrence control, indicating that the surgical choice is still the predominant factor for better prognoses of cervical chordomas.

Conclusions

Chordomas in the cervical spine usually represent an insidious neoplasms and have usually extended widely by the time of diagnosis. Radical intralesional tumor debulking surgery combined with postoperative radiotherapy remains an effective way to treat this disease. Because of the limited application of en bloc tumor resection and the active intralesional tumor seeding intraoperatively, the local recurrence rate is high, but there is little chance of distant metastatic disease. Most recurrent tumors present within 3 years. Some surgical techniques should be applied to minimize tumor seeding. Patients with upper cervical chordomas, younger adults, and the elderly are expected to have a worse prognosis. For patients in whom the tumor extends to both the anterior and posterior column, a total spondylectomy with piecemeal excision can help improve the prognosis.

Disclosure

The authors report no conflict of interest concerning the materials or methods used in this study or the findings specified in this paper.

Author contributions to the study and manuscript preparation include the following. Conception and design: Xiao, Y Wang. Acquisition of data: Y Wang, Wu, Q Huang, W Huang, Lin, Zhu, L Wang. Analysis and interpretation of data: Y Wang, Wu, Zhu. Drafting the article: Y Wang, Wu. Critically revising the article: all authors. Reviewed submitted version of manuscript: all authors. Approved the final version of the manuscript on behalf of all authors: Xiao. Statistical analysis: Y Wang, Lin. Administrative/technical/material support: Xiao, Q Huang, W Huang, L Wang. Study supervision: Y Wang, Q Huang.

References

1. Abe E, Sato K, Tazawa H, Murai H, Okada K, Shimada Y, et al: Total spondylectomy for primary tumor of the thoracolumbar spine. **Spinal Cord 38:**146–152, 2000
2. Austin JP, Urie MM, Cardenosa G, Munzenrider JE: Probable causes of recurrence in patients with chordoma and chondrosarcoma of the base of skull and cervical spine. **Int J Radiat Oncol Biol Phys 25:**439–444, 1993
3. Bailey CS, Fisher CG, Boyd MC, Dvorak MF: En bloc marginal excision of a multilevel cervical chordoma. Case report. **J Neurosurg Spine 4:**409–414, 2006
4. Barrenechea IJ, Perin NI, Triana A, Lesser J, Costantino P, Sen C: Surgical management of chordomas of the cervical spine. **J Neurosurg Spine 6:**398–406, 2007
5. Benk V, Liebsch NJ, Munzenrider JE, Efird J, McManus P, Suit H: Base of skull and cervical spine chordomas in children treated by high-dose irradiation. **Int J Radiat Oncol Biol Phys 31:**577–581, 1995
6. Bergh P, Kindblom LG, Gunterberg B, Remotti F, Ryd W, Meis-Kindblom JM: Prognostic factors in chordoma of the sacrum and mobile spine: a study of 39 patients. **Cancer 88:**2122–2134, 2000

7. Bjornsson J, Wold LE, Ebersold MJ, Laws ER: Chordoma of the mobile spine. A clinicopathologic analysis of 40 patients. **Cancer 71:**735–740, 1993
8. Boriani S, Bandiera S, Biagini R, Bacchini P, Boriani L, Cappuccio M, et al: Chordoma of the mobile spine: fifty years of experience. **Spine (Phila Pa 1976) 31:**493–503, 2006
9. Boriani S, Weinstein JN, Biagini R: Primary bone tumors of the spine. Terminology and surgical staging. **Spine (Phila Pa 1976) 22:**1036–1044, 1997
10. Bosma JJ, Pigott TJ, Pennie BH, Jaffray DC: En bloc removal of the lower lumbar vertebral body for chordoma. Report of two cases. **J Neurosurg 94 (2 Suppl):**284–291, 2001
11. Chambers PW, Schwinn CP: Chordoma. A clinicopathologic study of metastasis. **Am J Clin Pathol 72:**765–776, 1979
12. Cloyd JM, Chou D, Deviren V, Ames CP: En bloc resection of primary tumors of the cervical spine: report of two cases and systematic review of the literature. **Spine J 9:**928–935, 2009
13. Coffin CM, Swanson PE, Wick MR, Dehner LP: Chordoma in childhood and adolescence. A clinicopathologic analysis of 12 cases. **Arch Pathol Lab Med 117:**927–933, 1993
14. Delank KS, Kriegsmann J, Drees P, Eckardt A, Eysel P: Metastasizing chordoma of the lumbar spine. **Eur Spine J 11:**167–171, 2002
15. Firooznia H, Pinto RS, Lin JP, Baruch HH, Zausner J: Chordoma: radiologic evaluation of 20 cases. **AJR Am J Roentgenol 127:**797–805, 1976
16. Foweraker KL, Burton KE, Maynard SE, Jena R, Jefferies SJ, Laing RJ, et al: High-dose radiotherapy in the management of chordoma and chondrosarcoma of the skull base and cervical spine: Part 1—Clinical outcomes. **Clin Oncol (R Coll Radiol) 19:**509–516, 2007
17. Gwak HS, Yoo HJ, Youn SM, Chang U, Lee DH, Yoo SY, et al: Hypofractionated stereotactic radiation therapy for skull base and upper cervical chordoma and chondrosarcoma: preliminary results. **Stereotact Funct Neurosurg 83:**233–243, 2005
18. Higinbotham NL, Phillips RF, Farr HW, Hustu HO: Chordoma: thirty-five year study at Memorial Hospital. **Cancer 20:**1841–1850, 1967
19. Hoch BL, Nielsen GP, Liebsch NJ, Rosenberg AE: Base of skull chordomas in children and adolescents: a clinicopathologic study of 73 cases. **Am J Surg Pathol 30:**811–818, 2006
20. Hoshino Y, Kurokawa T, Nakamura K, Seichi A, Mamada T, Saita K, et al: A report on the safety of unilateral vertebral artery ligation during cervical spine surgery. **Spine (Phila Pa 1976) 21:**1454–1457, 1996
21. Iwasa Y, Nakashima Y, Okajima H, Morishita S: Sacral chordoma in early childhood: clinicopathological and immunohistochemical study. **Pediatr Dev Pathol 1:**420–426, 1998
22. Jawad MU, Scully SP: Surgery significantly improves survival in patients with chordoma. **Spine (Phila Pa 1976) 35:**117–123, 2010
23. Lee J, Bhatia NN, Hoang BH, Ziogas A, Zell JA: Analysis of prognostic factors for patients with chordoma with use of the California Cancer Registry. **J Bone Joint Surg Am 94:**356–363, 2012
24. Leitner Y, Shabat S, Boriani L, Boriani S: En bloc resection of a C4 chordoma: surgical technique. **Eur Spine J 16:**2238–2242, 2007
25. Matsumoto J, Towbin RB, Ball WS Jr: Cranial chordomas in infancy and childhood. A report of two cases and review of the literature. **Pediatr Radiol 20:**28–32, 1989
26. Matsumoto M, Watanabe K, Ishii K, Tsuji T, Takaishi H, Nakamura M, et al: Complicated surgical resection of malignant tumors in the upper cervical spine after failed ion-beam radiation therapy. **Spine (Phila Pa 1976) 35:**E505–E509, 2010
27. McGirt MJ, Gokaslan ZL, Chaichana KL: Preoperative grading scale to predict survival in patients undergoing resection of malignant primary osseous spinal neoplasms. **Spine (Phila Pa 1976) 11:**190–196, 2011
28. McMaster ML, Goldstein AM, Bromley CM, Ishibe N, Parry DM: Chordoma: incidence and survival patterns in the United States, 1973-1995. **Cancer Causes Control 12:**1–11, 2001
29. Molina C, Sciubba D, Gokaslan Z, Chou D, Wolinsky JP, Witham T, et al: En bloc resection of cervical chordomas: comparing outcomes to tumor position. Proceedings of the NASS 26th Annual Meeting. **Spine J 11:**152S, 2011 (Abstract)
30. Potluri S, Jefferies SJ, Jena R, Harris F, Burton KE, Prevost AT, et al: Residual postoperative tumour volume predicts outcome after high-dose radiotherapy for chordoma and chondrosarcoma of the skull base and spine. **Clin Oncol (R Coll Radiol) 23:**199–208, 2011
31. Ridenour RV III, Ahrens WA, Folpe AL, Miller DV: Clinical and histopathologic features of chordomas in children and young adults. **Pediatr Dev Pathol 13:**9–17, 2010
32. Rosenberg AE, Nielsen GP, Keel SB, Renard LG, Fitzek MM, Munzenrider JE, et al: Chondrosarcoma of the base of the skull: a clinicopathologic study of 200 cases with emphasis on its distinction from chordoma. **Am J Surg Pathol 23:**1370–1378, 1999
33. Schoenfield AJ, Pedlow FX, Hornicek FJ, Schwab JH: Chordoma of the mobile spine: a 15-year experience at the Massachusetts General Hospital. Proceedings of the NASS 25th Annual Meeting. **Spine J 10:**104S, 2010 (Abstract)
34. Sibley RK, Day DL, Dehner LP, Trueworthy RC: Metastasizing chordoma in early childhood: a pathological and immunohistochemical study with review of the literature. **Pediatr Pathol 7:**287–301, 1987
35. Soo MY: Chordoma: review of clinicoradiological features and factors affecting survival. **Australas Radiol 45:**427–434, 2001
36. Sundaresan N, Galicich JH, Chu FC, Huvos AG: Spinal chordomas. **J Neurosurg 50:**312–319, 1979
37. Tang SG, Byfield JE, Sharp TR, Utley JF, Quinol L, Seagren SL: Prognostic factors in the management of metastatic epidural spinal cord compression. **J Neurooncol 1:**21–28, 1983
38. Vieweg U, Meyer B, Schramm J: Tumour surgery of the upper cervical spine—a retrospective study of 13 cases. **Acta Neurochir (Wien) 143:**217–225, 2001
39. Zileli M, Kilinçer C, Ersahin Y, Cagli S: Primary tumors of the cervical spine: a retrospective review of 35 surgically managed cases. **Spine J 7:**165–173, 2007

Manuscript submitted February 20, 2012.
Accepted July 19, 2012.
Please include this information when citing this paper: published online August 24, 2012; DOI: 10.3171/2012.7.SPINE12175.
Address correspondence to: Jianru Xiao, M.D., The Spinal Tumor Center, Changzheng Hospital, 415 Fengyang Road, Shanghai 200003, China. email: fishking69@163.com.